

Treatment of Long COVID symptoms with triple anticoagulant therapy

Gert Laubshder

Mediclinic Stellenbosch

M Khan

Directorate of Respiratory Medicine, Manchester University Hospitals <https://orcid.org/0000-0003-1838-9002>

Chantelle Venter

Stellenbosch University

Jan Pretorius

Stellenbosch Univeristy

Douglas Kell

University of Liverpool <https://orcid.org/0000-0001-5838-7963>

Etheresia Pretorius (✉ resiap@sun.ac.za)

Stellenbosch University <https://orcid.org/0000-0002-9108-2384>

Article

Keywords: Long COVID, Symptoms, Co-morbidities, Amyloid Fibrin(ogen), Hyperactivated platelets

Posted Date: March 21st, 2023

DOI: <https://doi.org/10.21203/rs.3.rs-2697680/v1>

License:   This work is licensed under a Creative Commons Attribution 4.0 International License.

[Read Full License](#)

Abstract

Background: Fibrin(ogen) amyloid microclots and platelet hyperactivation are key pathological findings in patients with acute COVID-19 infection and also in those with Long COVID/Post-Acute Sequelae of COVID-19 (PASC). These pathologies may represent a suitable target for pharmacological treatment of Long COVID.

Methods: Here we report on the symptoms displayed by a cohort of 91 South African Long COVID patients at baseline and after a clinician-initiated anticoagulant regime was completed. For laboratory analysis, patients provided a blood sample before and after treatment. Fibrinolytic microclot presence was studied by adding thioflavin T to platelet poor plasma (PPP), whilst platelet hyperactivation was studied using two platelet markers- PAC1 and CD62P (P-selectin). The anticoagulant regime included dual antiplatelet therapy (DAPT- Clopidogrel 75mg + Aspirin 75mg) once a day, and a direct oral anticoagulant (DOAC- Apixaban) 5mg twice a day. A proton pump inhibitor (PPI) pantoprazole 40 mg/day was also prescribed for gastric protection. Each of the treated cases reported their main Long COVID symptoms, and whether their symptoms resolved following treatment or not.

Results: In our cohort a most participants did not report any comorbidities before acute COVID-19 infection. Hypertension and dyslipidaemia were the commonest underlying illnesses, whilst the most commonly reported Long COVID symptoms included fatigue, cognitive dysfunction, shortness of breath, and joint and muscle pains. Following completion of treatment, each of the different symptoms resolved in the majority of patients. This was also reflected in the laboratory analysis, where a decrease in the severity of fibrin amyloid microclotting and the degree of platelet pathology was noted. No serious adverse bleeding events were reported.

Conclusions: Fibrin amyloid microclots, platelet hyperactivation/ aggregation, and widespread endothelialitis inhibit the transport of oxygen at a capillary/cellular level. This provides a ready explanation for the symptoms of Long COVID. By normalizing the failed clotting physiology and reversal of the endothelialitis, triple anticoagulant therapy represents a promising treatment option that appears to be highly efficacious, and warrants controlled clinical studies. We caution that such a regime must only be followed under expert medical supervision in view of the risk of bleeding.

Introduction

Long COVID/Post-Acute Sequelae of COVID-19 (PASC) (hereafter referred to simply as Long COVID) has emerged as the most debilitating lingering sequela of acute Covid-19 infection ^{1, 2, 3, 4, 5, 6, 7, 8, 9, 10, 11}. As many of 30% of COVID-19 patients continue to suffer from persistent debilitating symptoms weeks or months after the acute infection. Fatigue is the most commonly reported symptom, followed by memory problems ¹².

From our perspective, a typical Long COVID patient is not one who has survived acute severe Covid-19 and is still struggling with symptoms of structural lung disease and deconditioning secondary to their

severe illness. Instead, we consider a Long COVID patient to be one who experiences an initial infection that can be either mild, asymptomatic, or severe, and subsequently experiences multiple continuing or new symptoms that persist for months. In previous work we^{13,14,15} and others have argued that the pathophysiology of Long COVID starts with damage to the endothelium (endothelialitis) secondary to the acute Covid-19 infection^{9,10,11}. Along with the widespread endothelialitis, individuals with Long COVID have widespread clotting and platelet abnormalities^{16,17}. If not adequately addressed during the acute phase, these pathologies become persistent. We have previously provided evidence that the persistent symptoms of Long COVID are due to continuation of the dysregulated clotting that originates during the acute phase and fails to resolve after recovery from the infective stage of the disease^{15,16,18,19,20}.

Previously we have argued that in the acute phase a single drug approach would be insufficient to address acute COVID-19 coagulopathy¹⁶. We suggested that the treatment of acute COVID-19 should be based on the results of point-of-care tests such as the TEG® as well as detailed analysis of microclot presence and platelet activation, to follow the physiological status of the hematological and coagulation system in real-time. It is our view that a multi-pronged approach guided by TEG® and platelet mapping is required to normalize clotting physiology in severe acute COVID-19 disease¹⁶.

In the current manuscript, we argue and provide evidence that a similar approach is also needed for the treatment of Long COVID. The appropriate use of a TEG® to exclude a hypocoagulable state can obviate the risk of significant bleeding.

We followed 91 patients who were diagnosed with Long COVID by our clinical collaborator (GJL). These patients were treated with a regime of anticoagulation which included dual antiplatelet therapy (DAPT- Clopidogrel 75mg/Aspirin 75mg) once a day, as well as a direct oral anticoagulant (DOAC- Apixaban) 5 mg twice a day. A proton pump inhibitor (PPI) pantoprazole 40 mg/day was routinely prescribed for gastric protection. For the laboratory analysis, patients provided blood samples before and after treatment. Fibrinoid microclot and platelet abnormalities were studied using fluorescence microscopy both before and after treatment. Patients reported their baseline Long COVID symptoms and whether these resolved following anticoagulation. The participants also scored their recovery using the Patient Global Impression of Change (PGIC) scale²¹. We also collected data on bleeding events whilst on treatment.

Materials And Methods

Ethical clearance

Ethical clearance for the study was obtained from the Health Research Ethics Committee (HREC) of Stellenbosch University (South Africa) (references N19/03/043, project ID 9521). The experimental objectives, risks, and details were explained to volunteers and informed consent was obtained prior to blood collection. Strict compliance to ethical guidelines and principles of the Declaration of Helsinki, South African Guidelines for Good Clinical Practice, and Medical Research Council Ethical Guidelines for

Research was kept for the duration of the study and for all research protocols. The laboratory scientists were not involved in developing or overseeing the drug treatment regime. The clinician would then initiate the anticoagulant treatment regimen. The laboratory team were allowed to collect blood samples from patients before and after treatment. Patients filled in the Patients Global Impression of Change (PGIC) scale²¹ at the end of the treatment period. The clinical intervention part of the paper was written by our clinician co-author (GJL). Blood sampling was performed at least four weeks apart, with the precise interval decided by the treating clinician.

Blood sample collection

A qualified phlebotomist or medical practitioner drew blood from 91 patients into citrated sample tubes (BD Vacutainer®, 369714) adhering to standard sterile protocol. Whole blood (WB) was centrifuged at 3000xg for 15 minutes at room temperature and the supernatant platelet poor plasma (PPP) samples were collected and stored in 1.5mL Eppendorf tubes at -80°C until analysis. Haematocrit samples were analysed on the day of collection.

Long COVID diagnosis

All 91 patients were evaluated for chronic conditions predating their acute COVID-19 infection. A diagnosis of Long COVID was entertained only after other pathology was excluded. Patients needed to have developed new and persistent symptoms after acute COVID-19 infection for a diagnosis of Long COVID and for inclusion in the study.

All patients underwent a full history of symptoms before and after acute COVID-19 infection, a relevant clinical examination, and appropriate investigations if clinician deemed it necessary, including the following: full blood count; N-terminal pro-B-type Natriuretic Peptide (NTproBNP) level; thyroid-stimulating hormone (TSH); C-reactive protein (CRP) level; the ratio between the concentrations of the enzymes aspartate transaminase and alanine transaminase (AST/ALT ratio); electrocardiography (EKG); and cardiac stress testing where indicated by the history. If there were a possible bleeding risk, TEG and/or PFA200 were done.

The following symptoms were identified as likely to be secondary to Long COVID and were included in the analysis: shortness of breath; chest pain; palpitations; fatigue; joint and/or muscle pain; cognitive dysfunction; gut symptoms; anxiety and/or depression; and sleep disturbance. These symptoms must not have been present before acute COVID-19 infection and needed to be persistent following acute COVID-19. See Fig. 1 for diagnostic algorithm.

Symptom and comorbidity data collection

All patients completed a checklist of comorbidities as part of the informed consent form. They also completed a checklist of symptoms present before and then after anticoagulant treatment. At the end of treatment, patients filled in the Patient Global Impression of Change (PGIC) scale²¹. (Table 1).

Table 1
Patient Global Impression of Change (PGIC) scale ²¹.

Since beginning treatment at clinic, how would you describe the change (if any) in activity limitations, symptoms, emotions and overall quality of life?	
No change (condition has worsened)	1
Almost the same, hardly any change at all	2
A little better, but no noticeable change	3
Somewhat better, but the change has not made a real difference	4
Moderately better and a slight, but noticeable change	5
Better, and a definite improvement that has made a real and worthwhile difference	6
A great deal better, a considerable improvement that has made all the difference	7

Platelet poor plasma (PPP) and the detection of amyloid (fibrin(ogen) protein and anomalous micro-clotting

Microclot formation in PPP samples was studied in all patients both before and after treatment. PPP was exposed to the fluorogenic amyloid dye Thioflavin T (ThT) (final concentration: 0,005mM) (Sigma-Aldrich, St. Louis, MO, USA) for 30 minutes (protected from light) at room temperature ^{22, 23, 24, 25}. After incubation, 3mL PPP was placed on a glass slide and covered with a coverslip. The excitation wavelength band for ThT was set at 450nm to 488nm and the emission at 499nm to 529nm. Processed samples were viewed using a Zeiss Axio Observer 7 fluorescent microscope with a Plan-Apochromat 63x/1.4 Oil DIC M27 objective (Carl Zeiss Microscopy, Munich, Germany) ^{19, 26, 27}.

Platelet pathology

Haematocrit samples of the cohort were exposed to two fluorescent markers: CD62P (PE-conjugated) (platelet surface P-selectin) (IM1759U, Beckman Coulter, Brea, CA, USA); and PAC-1 (FITC-conjugated) (340507, BD Biosciences, San Jose, CA, USA). CD62P is a marker for P-selectin that is located either on the membrane of platelets or inside them ^{17, 27}. PAC-1 identifies platelets through marking the glycoprotein IIb/IIIa (gpIIb/IIIa) on the platelet membrane. 4µL CD62P and 4µL PAC-1 were added to 20µL haematocrit, followed by incubation for 30 minutes (protected from light) at room temperature. The excitation wavelength band for PAC-1 was set at 450 to 488nm and the emission at 499 to 529nm, and for the CD62P marker it was 540nm to 570nm and the emission at 577nm to 607nm. Samples were viewed using a Zeiss Axio Observer 7 fluorescent microscope with a Plan-Apochromat 63x/1.4 Oil DIC M27 objective (Carl Zeiss Microscopy, Munich, Germany).

Anticoagulant treatment regimen

All 91 Long COVID patients identified by our clinical collaborator (GJL) were found to have microclot and platelet pathology. Informed consent was then taken for commencement of anticoagulant treatment.

Patients were informed that this is not yet standard treatment for Long COVID. Patients were excluded if they had any contra-indications to any anticoagulants.

Patients were started on dual antiplatelet therapy (DAPT- clopidogrel 75mg and aspirin 75mg) once a day, as well as a direct oral anticoagulant (DOAC- apixaban 5 mg) twice a day. A proton pump inhibitor (PPI- pantoprazole 40 mg/day) taken orally half an hour before main meal was added for gastric protection. The average time from acute COVID infection to commencement of treatment was 10 months. Patients with 'short' Long COVID (symptoms less than 6 months) usually needed treatment for 2–4 months, while those with 'long' Long COVID (symptoms more than 6 months), needed 4–6 months (or longer) of treatment.

Blood samples from patients were analysed two weeks after commencement of treatment using thromboelastography (TEG®) ^{16,28} and the PFA200 platelet function analyser ²⁹. These analyses were done to ensure that a hypocoagulable state putting the patient at risk of bleeding had not been induced ³⁰, and to rule out clopidogrel and/or aspirin resistance ^{31,32,33,34}. If clopidogrel resistance was observed, it was replaced with Ticagrelor 90 mg bd.

Presentation of data and statistical analysis of comorbidities, self-reported symptoms, bleeding propensity and flow cytometry data

Analysis of comorbidities and Long COVID symptoms was conducted with R-statistical software (version 4.2.2) and Microsoft Excel. The deidentified data were arrayed in a suitable format for visual statistical analysis with the dplyr package in R and then further adjusted manually in Excel. Graphical representations were produced in R with the ggplot2 and networkD3 libraries.

Results

Comorbidities and self-reported symptoms before and after treatment

Table 2 and Figs. 2 to 5 describe the clinical characteristics of the 91 participants. Data were analysed according to comorbidities, Long COVID symptoms and response to treatment using a Sankey plot, violin plot and a pyramid plot. Patients were also asked about their initial acute COVID-19 symptoms and it included if they were hospitalized, received oxygen or were ventilated. Hypertension (systolic > 140 mmHg) and dyslipidaemia (cholesterol > 5.5 mmol.L), were the commonest comorbidities.

Table 2
Demographics, comorbidities and symptom status of 91 Long COVID patients before and after treatment.

Demographics of sub-group of 91 Long COVID patients			
Age	50 (\pm 14)		
Gender	Females	54	Males 37
Acute COVID			
12 hospitalized (13%)	10 received oxygen (11%)	4 ventilated (4%)	
Comorbidities			
Comorbidities	Number of patients and %		
High total cholesterol (> 5.5 mmol.L)	24 patients (26%)		
High blood pressure (> 140 mmHg)	16 patients (18%)		
Gut dysbiosis or leaky gut symptoms	6 patients (7%)		
Cardiovascular disease	7 patients (8%)		
Rheumatoid arthritis	3 patients (3%)		
Gingivitis and/or Periodontitis	3 patients (3%)		
Psoriasis	1 patients (1%)		
Type 2 diabetes mellitus	1 patients 1%)		
Previous cancer	1 patients (1%)		
Rosacea	1 patients (1%)		

Figure 2 illustrates the age distribution of Long COVID symptoms at baseline in our cohort of 91 patients. Symptom distribution was mostly uniform across age. In our cohort, we had 54 females and 37 male participants.

Figure 3 is a Sankey plot illustrating the relationship between comorbidities and symptom prevalence before and after treatment (see also Table 3). Patients reported their Long COVID symptoms before treatment and then after treatment when blood was re-sampled. If a symptom was no longer present after treatment it was reported in Fig. 3 as 'improved'.

Figure 4 shows the response to treatment of the various symptoms reported as the percentage of patients in whom a particular symptom improved. Not all patients reported the same symptoms and therefore there exists large heterogeneity in the data. Some patients reported improvement in all symptoms; some symptoms persisted in others.

Table 3
Long COVID symptoms, before and after treatment.

Long COVID Symptoms		
Symptom	Patients with symptom before treatment	Patients with symptom after treatment
Cognitive dysfunction	82 patients	21 patients
Fatigue	81 patients	18 patients
Shortness of breath	61 patients	11 patients
Muscle and/or joint pain	52 patients	12 patients
Depression and/or anxiety	43 patients	8 patients
Sleep disturbance	50 patients	11 patients
Palpitations	51 patients	7 patients
Chest pain	32 patients	6 patients
Digestive problems	26 patients	6 patients

For the purpose of analysis of the PGIC data, we divided the patients into two groups based on the duration of their long COVID. We defined 'short' long COVID as up to 6 months of persistent symptoms after the episode of acute COVID-19, and 'long' Long COVID as more than 6 months of persistent symptoms after the episode of acute COVID-19. Figure 5 shows the PGIC scores within the two cohorts: 'short' Long COVID and 'long' Long COVID. The median PGIC score for the whole cohort was 6.

The patients also reported on side effects whilst on treatment. Most of the patients (75) reported the occurrence of bruising (after slight bumps) in the form of ecchymoses (discoloration of the skin resulting from bleeding underneath) - a common but not serious event. This bruising occurred e.g. after slight bumps. after Five patients experienced minor nosebleeds. Three patients reported bleeding after a finger cut, out of whom one required medical intervention. Two female participants reported increased menstrual bleeding. One of the female participants required a blood transfusion whilst on the treatment due to a gastrointestinal (GIT) bleed- notably, this individual did not report recovery and had a PGIC score of 1.

Laboratory blood analysis

The current microclot and platelet analysis showed significant microclotting and platelet pathology in all patients before treatment. See Figs. 6 and 7 for representative microscopy results of patients who reported recovery, and Fig. 8 for representative microscopy of those who did not report recovery at follow-up blood sampling.

Discussion

Our previous work ^{14, 15, 16, 18}, provides preliminary evidence that fibrin amyloid microclots and platelet hyperactivation are likely to play a significant role in the pathophysiology of Long COVID symptoms. Due to a combination of microclot formation, platelet aggregates and endothelialitis a defect in oxygen transfer at a capillary level arises, leading to tissue hypoxia ¹⁴. This leads to mitochondrial failure (reduced energy production) giving rise to multiple symptoms. Not all organs in the body have the same partial pressure of oxygen under normal circumstances ³⁵. The lung has the highest partial pressure of oxygen of 100–110 mmHg, whilst the corresponding value in the brain is only 35–40 mmHg ³⁵. This makes the brain more prone to cellular hypoxia. Apart from the brain, the eye, skin, muscle (including myocardium), femur, vestibular apparatus and placenta have the lowest partial pressure of oxygen under normal circumstances ³⁵; it is these organs where many Long COVID symptoms originate from ^{14, 15}.

The symptoms of Long COVID typically fluctuate. We argue that this is likely to be due to the build-up of a cellular 'reservoir' of oxygen in the resting state- during these phases patients may feel much better or even normal. In the event of physical, cognitive or emotional exertion, the metabolic rate goes up and there comes a point when the oxygen 'reservoir' is depleted. Oxygen transfer at the cellular level fails due to the presence of abnormal clotting and endothelialitis, causing a 'crash' with worsening symptoms. The 'crash' is also known as post-exertional symptom exacerbation (PESE) or post-exertional malaise (PEM) and is also seen in myalgic encephalomyelitis (ME/CFS) ^{36, 37, 38, 39, 40}. The concept of the oxygen 'reservoir' may also explain why patients who pace their activities can remain active for longer without crashing.

Many patients also exhibit a postural orthostatic tachycardia syndrome (POTS)-like picture ⁴¹. We suggest that these patients- at least initially- do **not** have autonomic failure. The following equation is key to understanding this:

Blood Pressure (Bp) = cardiac Output (Co) X Peripheral Resistance (Pr)

Following a (postural) drop in blood pressure the autonomic nervous system restores the blood pressure by sympathetic stimulation of CO (heart rate x stroke volume) and also through increased peripheral resistance (secondary to the effect of norepinephrine on the endothelium and vascular smooth muscle) ³⁵. Because of endothelial damage, this message does not get to the vascular smooth muscle, resulting in a failure to increase peripheral resistance. The only mechanism left to increase/maintain BP is the sympathetic effect on the heart rate, which explains the palpitations and tachycardia reported by patients following postural change or minimal exertion. Therefore we suggest that the postural exaggeration of heart rate is not due to autonomic failure, but due to endothelial failure- at least in the early stages of the illness.

Given the aforementioned mechanism by which microclots and platelet hyperactivation can result in Long COVID symptoms, it is reasonable to infer that anticoagulants- which have potential benefit in acute COVID treatment ⁴²- could be of therapeutic value in Long COVID. In the current study, we have demonstrated that a triple anticoagulant regime can resolve symptoms in the majority of patients. In addition, there is a marked improvement in the PGIC (median = 6) score which encompasses activity limitation, symptoms, emotions and quality of life.

The purpose of the anticoagulant regime was to reverse the pathological hypercoagulable state and restore normal clotting physiology- the aim was **not** to make the patient hypocoagulable. With negative outcomes in single agent trials in acute COVID, the erroneous conclusion could be drawn that there is no place for anticoagulation in Long COVID either ^{43, 44, 45, 46, 47, 48}. We chose three drugs so that both the enzymatic pathway of coagulation and platelet hyperactivation could be targeted adequately. DOACs act at different points of the enzymatic clotting pathway ⁴⁹, whilst platelet hyperactivation is prevented by DAPT ^{50, 51}. Aspirin targets the COX-1 receptor, and clopidogrel the P2Y receptor on platelets- hence the need for both drugs. Figure 9 shows the mode of action of various drugs targeting the enzymatic pathway and platelet hyperactivation ^{49, 50, 51}. This 'triple therapy' regime therefore prevents platelet hyperactivation and prevents new microclots from forming, whilst allowing the body's own fibrinolysis pathways to clear existing microclots.

Out of 91 treated patients, 75 reported bruising that did not require medical attention. Five patients reported minor epistaxis, two female participants experienced increased menstrual bleeding, and one sustained a gastrointestinal bleed necessitating hospitalization and a 2 unit blood transfusion. Three patients reported bleeding after they cut themselves, of whom one required medical attention. We propose that the reason for the relatively low bleeding risk of Long COVID patients on triple therapy is due to the underlying pathophysiology which induces a hypercoagulable state. The rate of significant bleeding in our series compares favorably to the incidence of adverse bleeding events quoted in trials of DOACs in chronic atrial fibrillation (2.5–3.5%) ^{52, 53, 54}. In atrial fibrillation the aim of anticoagulation is to prevent clotting by making the patient hypocoagulable, whereas in Long COVID the aim is to normalize clotting physiology whilst allowing the natural removal of existing microclots by the body's fibrinolytic system.

Conclusion

In the current study, all 91 patients with a clinical diagnosis of Long COVID displayed platelet hyperactivation and microclot formation. Patients were treated with a regime of 'triple' therapy comprised of DAPT and a DOAC. The combination addresses the hypercoagulable state and restores normal clotting physiology, prevents platelet hyperactivation and allows the endothelium to heal and regain function. Fluorescence microscopy performed before and after treatment revealed a significant visual reduction in microclotting and platelet hyperactivation. There was a marked reduction in individual symptoms in the majority of patients, as well as an improvement in PGIC .

We argue that our proposed therapeutic regimen is safe and effective. Delay in treatment may prolong the duration of pharmacotherapy and also increase the likelihood of permanent hypoxic tissue damage. This may manifest as a partial response to treatment or even treatment failure.

It is important that clinicians and patients are aware that this treatment protocol remains experimental for the time being. It should only be used by expert physicians with a thorough understanding of clotting physiology, including the specific abnormalities seen in Long COVID. Patients need to be counseled regarding the relative risks and benefits of treatment, and require close clinical supervision.

Randomised, double-blind, placebo-controlled trials of anticoagulant therapy with objective endpoints are required to define the optimum combination of drugs and duration of treatment, and to accurately quantify the risk of adverse events. Given the huge and continuously growing global burden of Long COVID, there is some urgency to this need.

Declarations

Acknowledgements

We wish to thank all the Long COVID patients who participated in this study. Also, Lezette Briedenhann, Ilse Geldenhuys and Anneke De Villiers who curated the patient consents and blood collections at the clinical practice.

Funding

DBK thanks the Novo Nordisk Foundation (grant NNF20CC0035580) for financial support. EP acknowledges the South African Medical Research Council and the NRF (grant number: 142142). The funders had no role in study design, data collection and analysis, decision to publish, or preparation of the manuscript.

Consent for publication

All authors approved submission of the paper.

Competing interests

EP is the managing director of BioCODE Technologies. The other authors have no competing interests to declare.

Authors' contributions

GLJ: patient identification, clinical collaborator; editing of paper MAC: clinical advice and editing of paper; CV: curating of samples, platelet analysis; JHP: statistical analysis and data preparation; DBK: editing of paper and co-corresponding author; EP: study leader, writing of paper, funding, corresponding author.

References

1. Tabacof L, *et al.* Post-acute COVID-19 Syndrome Negatively Impacts Physical Function, Cognitive Function, Health-Related Quality of Life, and Participation. *Am J Phys Med Rehabil***101**, 48-52 (2022).
2. Proal AD, VanElzakker MB. Long COVID or Post-acute sequelae of COVID-19 (PASC): An overview of 1 biological factors that may contribute to persistent symptoms. *Frontiers in Microbiology***In Press**, (2021).
3. Deer RR, *et al.* Characterizing Long COVID: Deep Phenotype of a Complex Condition. *EBioMedicine***74**, 103722 (2021).
4. Davis HE, *et al.* Characterizing long COVID in an international cohort: 7 months of symptoms and their impact. *EClinicalMedicine***38**, 101019 (2021).
5. Al-Aly Z, Xie Y, Bowe B. High-dimensional characterization of post-acute sequelae of COVID-19. *Nature***594**, 259-264 (2021).
6. Al-Aly Z, Bowe B, Xie Y. Long COVID after breakthrough SARS-CoV-2 infection. *Nat Med***28**, 1461-1467 (2022).
7. Xie Y, Xu E, Bowe B, Al-Aly Z. Long-term cardiovascular outcomes of COVID-19. *Nat Med***28**, 583-590 (2022).
8. Wulf Hanson S, *et al.* Estimated Global Proportions of Individuals With Persistent Fatigue, Cognitive, and Respiratory Symptom Clusters Following Symptomatic COVID-19 in 2020 and 2021. *Jama***328**, 1604-1615 (2022).
9. Raman B, Bluemke DA, Lüscher TF, Neubauer S. Long COVID: post-acute sequelae of COVID-19 with a cardiovascular focus. *Eur Heart J***43**, 1157-1172 (2022).
10. Nurek M, *et al.* Recommendations for the recognition, diagnosis, and management of long COVID: a Delphi study. *Br J Gen Pract***71**, e815-e825 (2021).
11. Nalbandian A, *et al.* Post-acute COVID-19 syndrome. *Nat Med***27**, 601-615 (2021).
12. Chen C, Hauptert SR, Zimmermann L, Shi X, Fritsche LG, Mukherjee B. Global Prevalence of Post-Coronavirus Disease 2019 (COVID-19) Condition or Long COVID: A Meta-Analysis and Systematic Review. *J Infect Dis***226**, 1593-1607 (2022).
13. Pretorius E, *et al.* Persistent clotting protein pathology in Long COVID/ Post-Acute Sequelae of COVID-19 (PASC) is accompanied by increased levels of antiplasmin. *medRxiv*, 2021.2005.2021.21257578 (2021).
14. Kell DB, Pretorius E. The potential role of ischaemia-reperfusion injury in chronic, relapsing diseases such as rheumatoid arthritis, Long COVID, and ME/CFS: evidence, mechanisms, and therapeutic implications. *Biochem J***479**, 1653-1708 (2022).

15. Kell DB, Laubscher GJ, Pretorius E. A central role for amyloid fibrin microclots in long COVID/PASC: origins and therapeutic implications. *Biochem J***479**, 537-559 (2022).
16. Laubscher GJ, Lourens PJ, Venter C, Kell DB, Pretorius E. TEG®, Microclot and Platelet Mapping for Guiding Early Management of Severe COVID-19 Coagulopathy. *Journal of Clinical Medicine***10**, (2021).
17. Grobler C, *et al.* Covid-19: The Rollercoaster of Fibrin(Ogen), D-Dimer, Von Willebrand Factor, P-Selectin and Their Interactions with Endothelial Cells, Platelets and Erythrocytes. *Int J Mol Sci***21**, (2020).
18. Pretorius E, *et al.* Persistent clotting protein pathology in Long COVID/Post-Acute Sequelae of COVID-19 (PASC) is accompanied by increased levels of antiplasmin. *Cardiovasc Diabetol***20**, 172 (2021).
19. Pretorius E, Venter C, Laubscher GJ, Lourens PJ, Steenkamp J, Kell DB. Prevalence of readily detected amyloid blood clots in 'unclotted' Type 2 Diabetes Mellitus and COVID-19 plasma: a preliminary report. *Cardiovasc Diabetol***19**, 193 (2020).
20. Kruger A, *et al.* Proteomics of fibrin amyloid microclots in long COVID/post-acute sequelae of COVID-19 (PASC) shows many entrapped pro-inflammatory molecules that may also contribute to a failed fibrinolytic system. *Cardiovasc Diabetol***21**, 190 (2022).
21. Hurst H, Bolton J. Assessing the clinical significance of change scores recorded on subjective outcome measures. *J Manipulative Physiol Ther***27**, 26-35 (2004).
22. Kell DB, Pretorius E. Proteins behaving badly. Substoichiometric molecular control and amplification of the initiation and nature of amyloid fibril formation: lessons from and for blood clotting. *Prog Biophys Mol Biol***123**, 16-41 (2017).
23. Page MJ, *et al.* Serum amyloid A binds to fibrin(ogen), promoting fibrin amyloid formation. *Sci Rep***9**, 3102 (2019).
24. Pretorius E, Mbotwe S, Kell DB. Lipopolysaccharide-binding protein (LBP) reverses the amyloid state of fibrin seen in plasma of type 2 diabetics with cardiovascular co-morbidities. *Sci Rep***7**, 9680 (2017).
25. Pretorius E, Page MJ, Engelbrecht L, Ellis GC, Kell DB. Substantial fibrin amyloidogenesis in type 2 diabetes assessed using amyloid-selective fluorescent stains. *Cardiovasc Diabetol***16**, 141 (2017).
26. Grobbelaar LM, *et al.* SARS-CoV-2 spike protein S1 induces fibrin(ogen) resistant to fibrinolysis: Implications for microclot formation in COVID-19. *medRxiv*, 2021.2003.2005.21252960 (2021).
27. Venter C, *et al.* Erythrocyte, Platelet, Serum Ferritin, and P-Selectin Pathophysiology Implicated in Severe Hypercoagulation and Vascular Complications in COVID-19. *Int J Mol Sci***21**, (2020).
28. Dirican A, Ildir S, Uzar T, Karaman I, Ozkaya S. The role of endotheliitis in COVID-19: Real-world experience of 11 190 patients and literature review for a pathophysiological map to clinical categorisation. *Int J Clin Pract***75**, e14843 (2021).
29. Favaloro EJ, Bonar R. An update on quality control for the PFA-100/PFA-200. *Platelets***29**, 622-627 (2018).

30. Brown DL, *et al.* Benefits and Risks of Dual Versus Single Antiplatelet Therapy for Secondary Stroke Prevention: A Systematic Review for the 2021 Guideline for the Prevention of Stroke in Patients With Stroke and Transient Ischemic Attack. *Stroke***52**, e468-e479 (2021).
31. Hankey GJ, Eikelboom JW. Aspirin resistance. *Lancet***367**, 606-617 (2006).
32. Guirgis M, Thompson P, Jansen S. Review of aspirin and clopidogrel resistance in peripheral arterial disease. *J Vasc Surg***66**, 1576-1586 (2017).
33. Khan H, Kanny O, Syed MH, Qadura M. Aspirin Resistance in Vascular Disease: A Review Highlighting the Critical Need for Improved Point-of-Care Testing and Personalized Therapy. *Int J Mol Sci***23**, (2022).
34. Ray S. Clopidogrel resistance: the way forward. *Indian Heart J***66**, 530-534 (2014).
35. Ortiz-Prado E, Dunn JF, Vasconez J, Castillo D, Viscor G. Partial pressure of oxygen in the human body: a general review. *Am J Blood Res***9**, 1-14 (2019).
36. Paul BD, Lemle MD, Komaroff AL, Snyder SH. Redox imbalance links COVID-19 and myalgic encephalomyelitis/chronic fatigue syndrome. *Proceedings of the National Academy of Sciences***118**, e2024358118 (2021).
37. Singh I, *et al.* Persistent Exertional Intolerance After COVID-19: Insights From Invasive Cardiopulmonary Exercise Testing. *Chest*, (2021).
38. Stussman B, *et al.* Characterization of Post-exertional Malaise in Patients With Myalgic Encephalomyelitis/Chronic Fatigue Syndrome. *Front Neuro***11**, 1025 (2020).
39. Twomey R, DeMars J, Franklin K, Culos-Reed SN, Weatherald J, Wrightson JG. Chronic Fatigue and Postexertional Malaise in People Living With Long COVID: An Observational Study. *Phys Ther***102**, (2022).
40. Wright J, Astill SL, Sivan M. The Relationship between Physical Activity and Long COVID: A Cross-Sectional Study. *Int J Environ Res Public Health***19**, (2022).
41. Raj SR, *et al.* Long-COVID postural tachycardia syndrome: an American Autonomic Society statement. *Clin Auton Res***31**, 365-368 (2021).
42. Investigators WCftr-C. Long-term (180-Day) Outcomes in Critically Ill Patients With COVID-19 in the REMAP-CAP Randomized Clinical Trial. *JAMA***329**, 39-51 (2023).
43. Spyropoulos AC, Bonaca MP. Studying the coagulopathy of COVID-19. *Lancet***399**, 118-119 (2022).
44. Connors JM, *et al.* Effect of Antithrombotic Therapy on Clinical Outcomes in Outpatients With Clinically Stable Symptomatic COVID-19: The ACTIV-4B Randomized Clinical Trial. *Jama***326**, 1703-1712 (2021).
45. Lopes RD, *et al.* Therapeutic versus prophylactic anticoagulation for patients admitted to hospital with COVID-19 and elevated D-dimer concentration (ACTION): an open-label, multicentre, randomised, controlled trial. *Lancet***397**, 2253-2263 (2021).
46. Sadeghipour P, *et al.* Effect of Intermediate-Dose vs Standard-Dose Prophylactic Anticoagulation on Thrombotic Events, Extracorporeal Membrane Oxygenation Treatment, or Mortality Among Patients

- With COVID-19 Admitted to the Intensive Care Unit: The INSPIRATION Randomized Clinical Trial. *Jama***325**, 1620-1630 (2021).
47. Investigators A, *et al.* Therapeutic Anticoagulation with Heparin in Noncritically Ill Patients with Covid-19. *N Engl J Med***385**, 790-802 (2021).
 48. Group RC. Aspirin in patients admitted to hospital with COVID-19 (RECOVERY): a randomised, controlled, open-label, platform trial. *Lancet***399**, 143-151 (2022).
 49. Eller T, *et al.* Dabigatran, rivaroxaban, apixaban, argatroban and fondaparinux and their effects on coagulation POC and platelet function tests. *Clin Chem Lab Med***52**, 835-844 (2014).
 50. Cattaneo M. P2Y12 receptors: structure and function. *J Thromb Haemost***13 Suppl 1**, S10-16 (2015).
 51. Scharf RE. Drugs that affect platelet function. *Semin Thromb Hemost***38**, 865-883 (2012).
 52. Connolly SJ, *et al.* Dabigatran versus warfarin in patients with atrial fibrillation. *N Engl J Med***361**, 1139-1151 (2009).
 53. Patel MR, *et al.* Rivaroxaban versus warfarin in nonvalvular atrial fibrillation. *N Engl J Med***365**, 883-891 (2011).
 54. Granger CB, *et al.* Apixaban versus warfarin in patients with atrial fibrillation. *N Engl J Med***365**, 981-992 (2011).

Figures

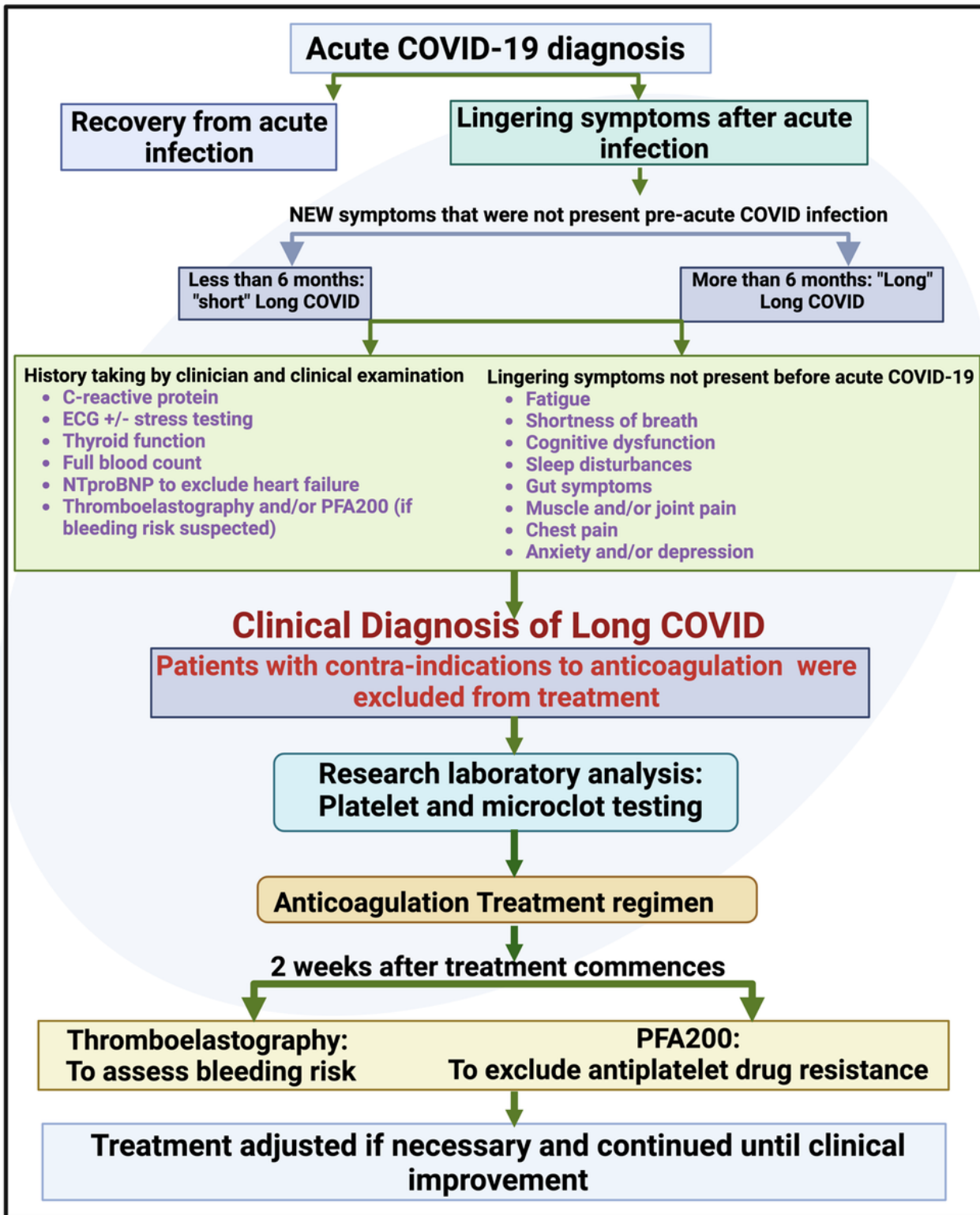


Figure 1

Long COVID route from diagnosis to treatment.

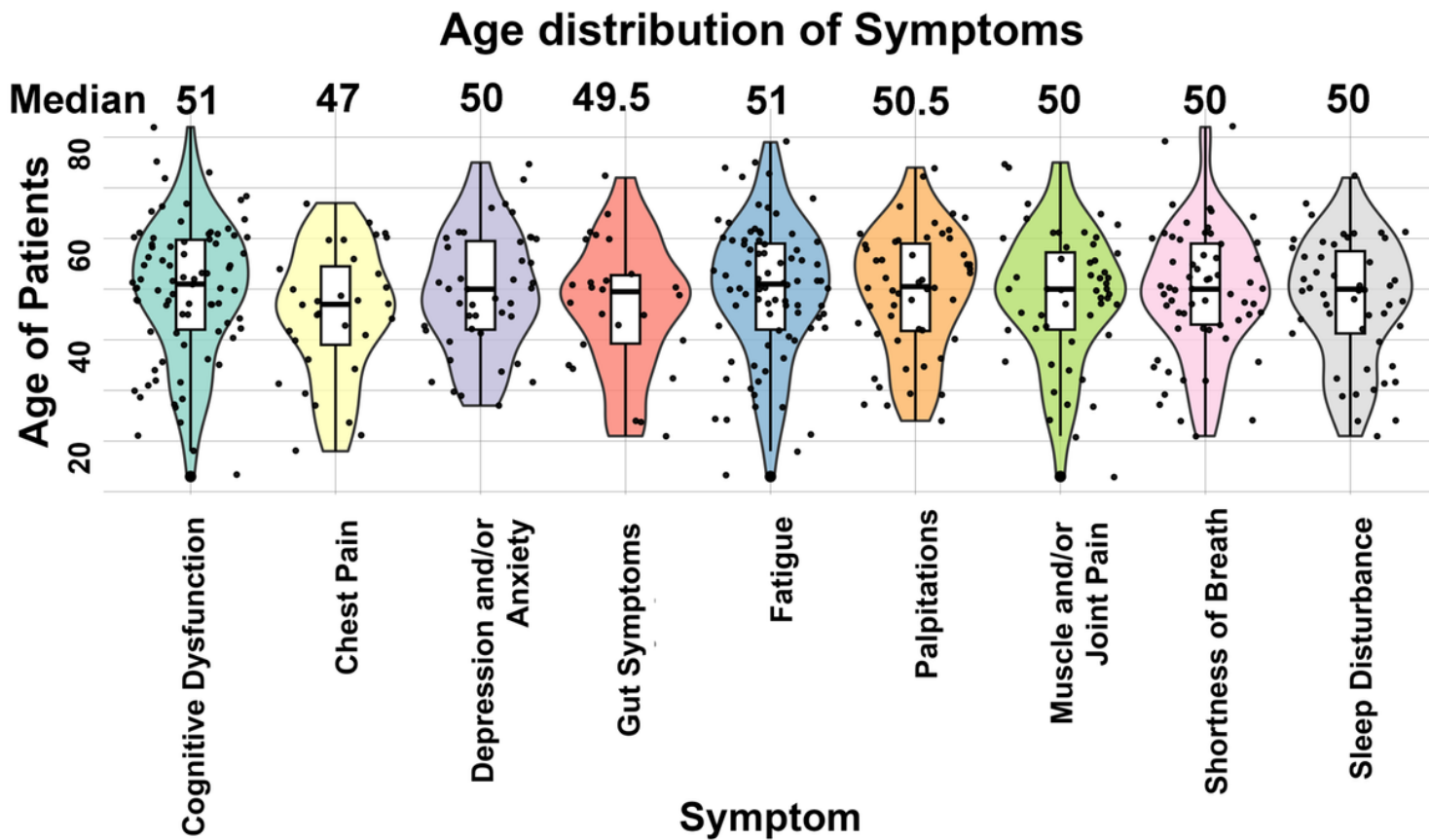


Figure 2

Violin plot showing the distribution of symptoms according to age.

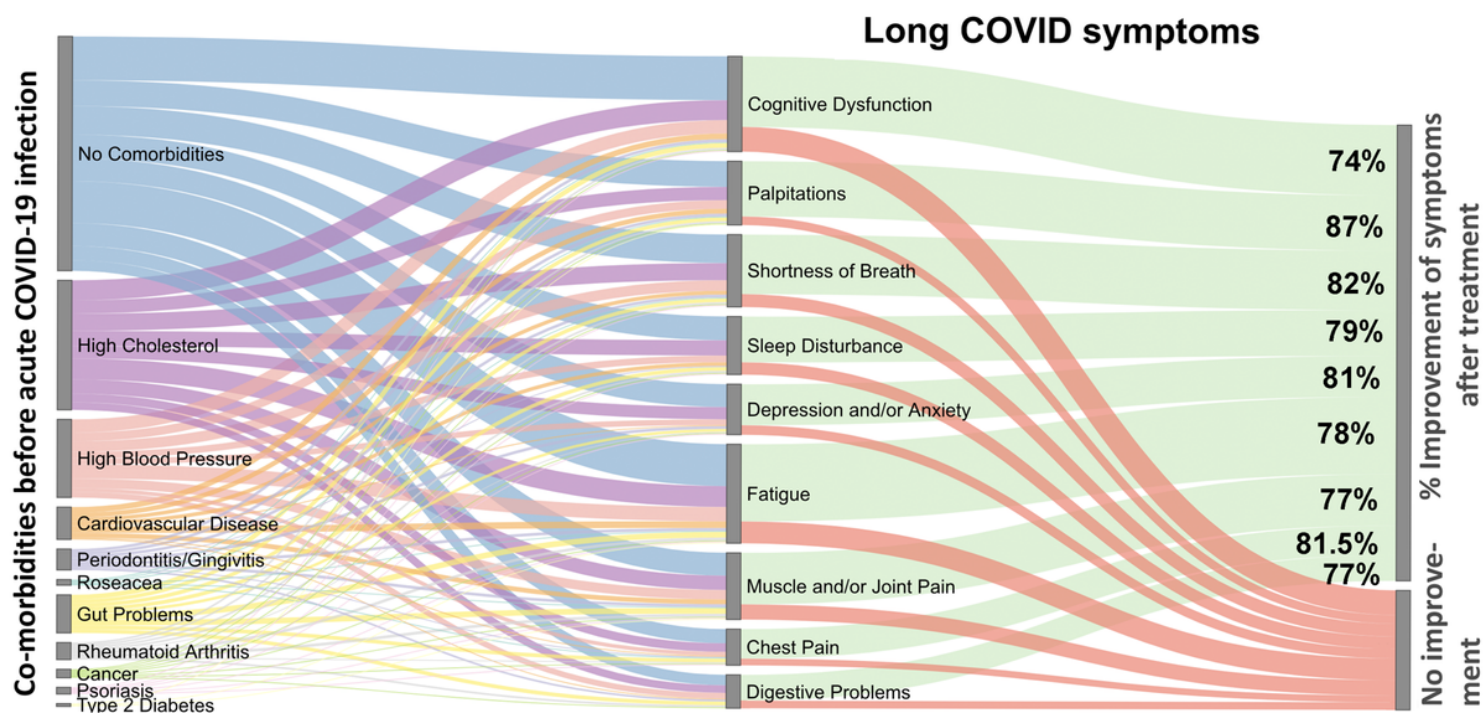


Figure 3

Sankey plot illustrating the relationship between comorbidities and symptom prevalence before and after treatment in the 91 patient cohort. Patients reported their Long COVID symptoms before treatment and then upon re-sampling of blood after treatment. The Sankey plot represents the % of patients who improved for each symptom (not total % improvement).

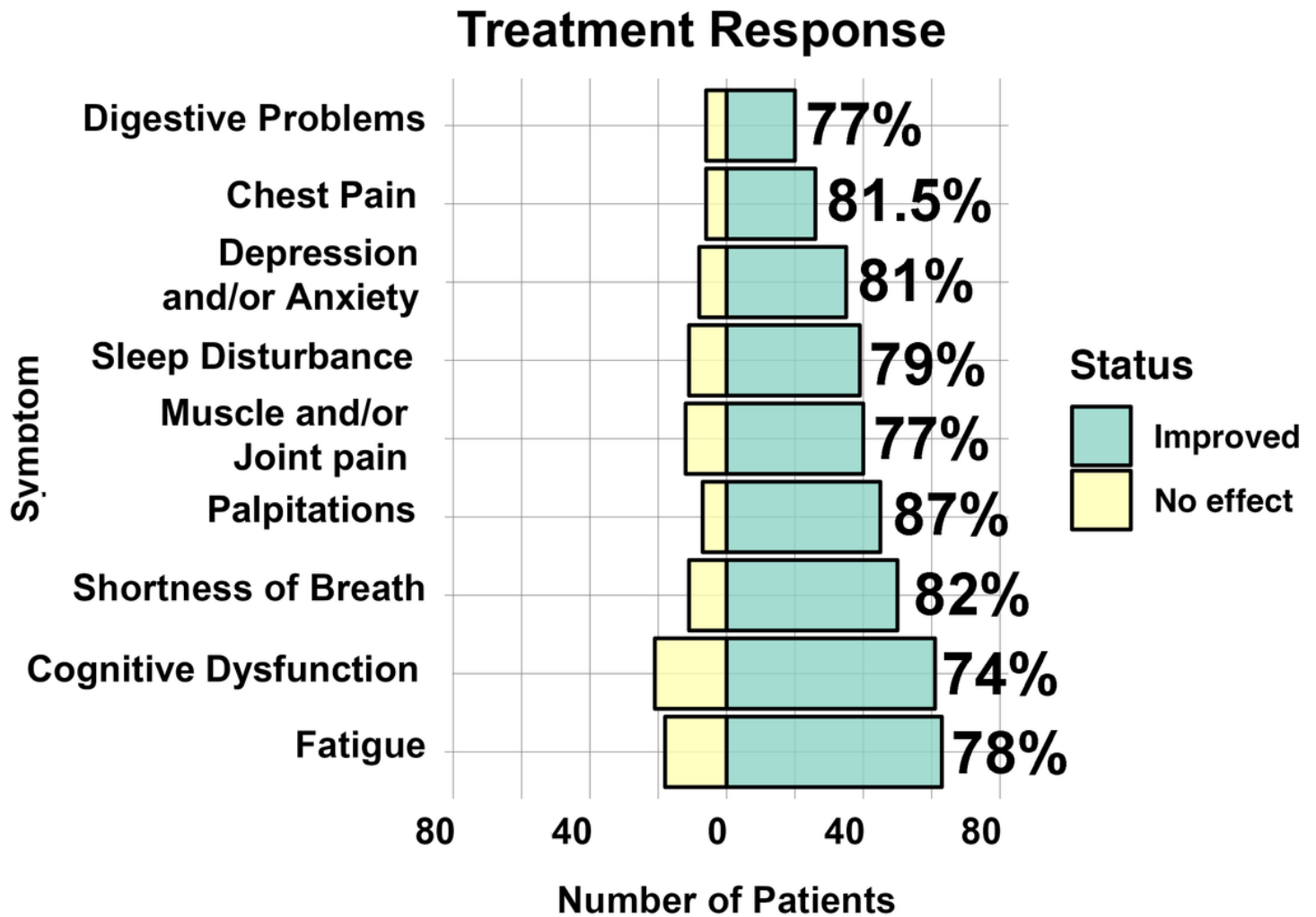


Figure 4

Treatment response of the 91 patients. Patients were asked to report the presence of symptoms before and after treatment. If a symptom was no longer present after treatment it was reported in the plot below as 'improved'.

Histogram of PGIC Scores of Patients

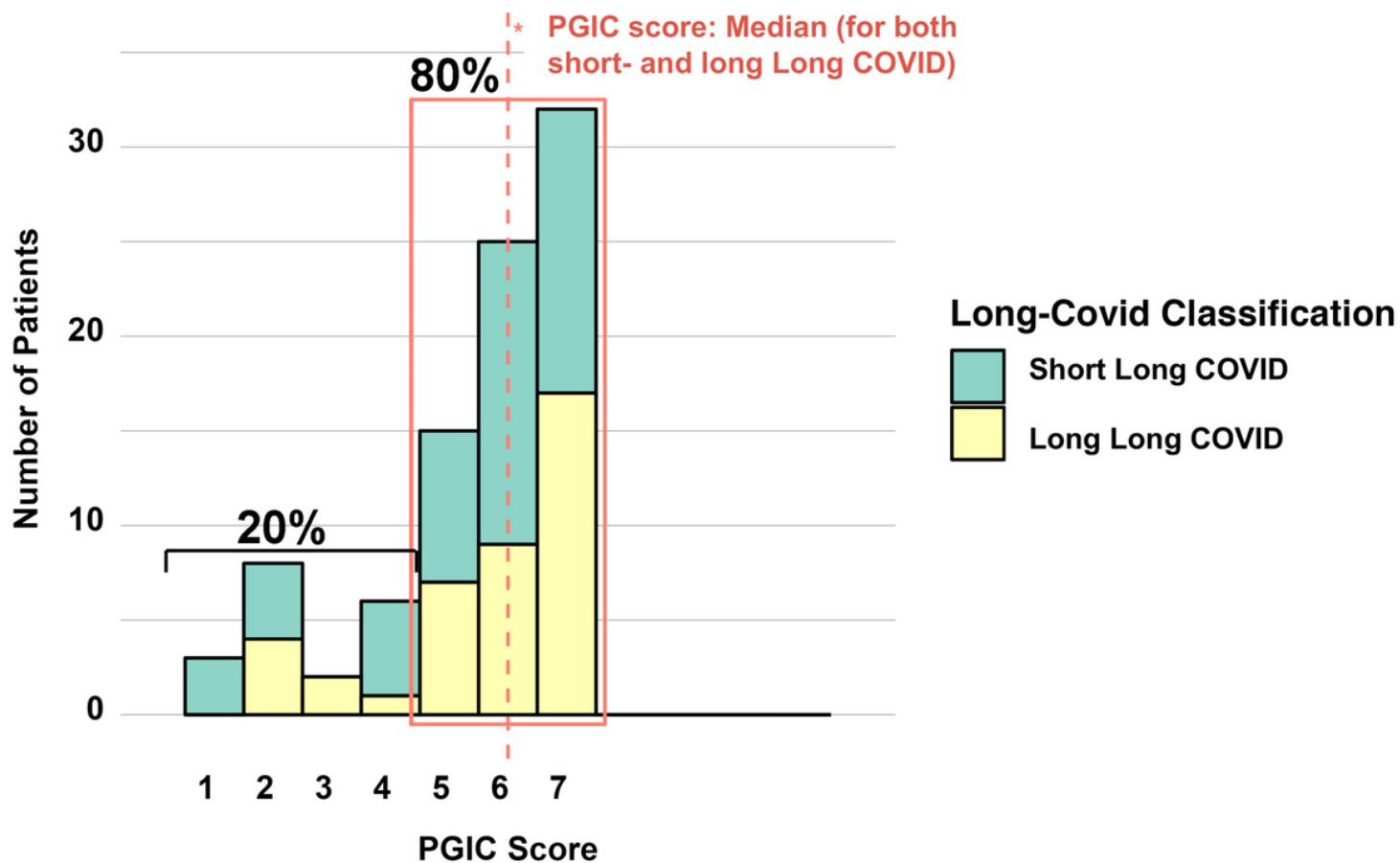


Figure 5

Self-reported scoring using the Patient Global Impression of Change (PGIC) scale²¹. The plot shows the percentage of individuals who reported no or little recovery (PGIC score 1 to 4) and those who reported recovery (5 to 7) for both 'short' Long COVID and 'long' Long COVID. ('Short' long COVID: up to six months of symptoms after acute COVID-19; 'long' Long COVID: more than 6 months of symptoms after acute COVID19.) See Table 1 for an explanation of the PGIC²¹.

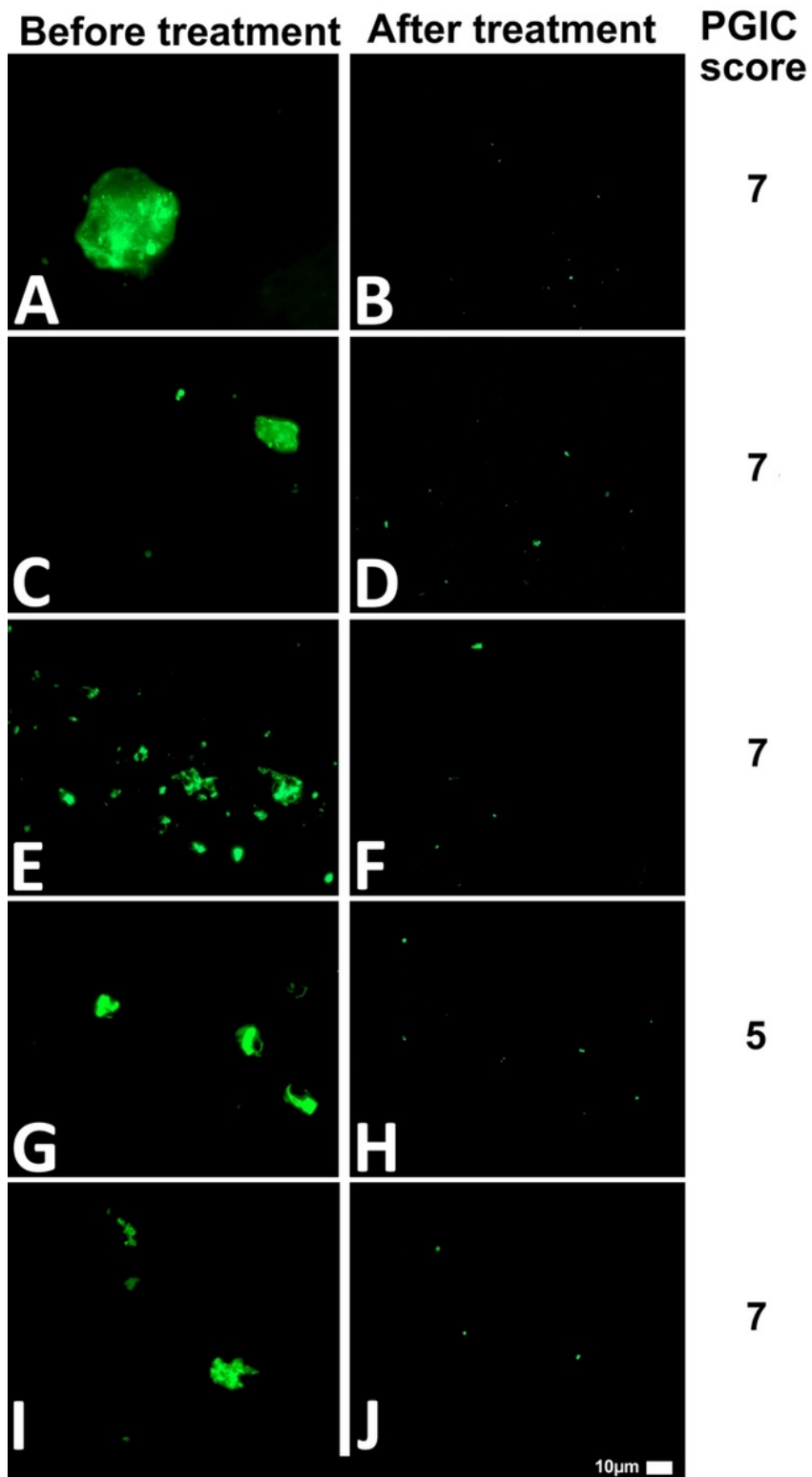


Figure 6

Representative platelet poor plasma (PPP) fluorescence micrographs with moderate areas of plasma protein misfolding forming microclots (some larger than 15µm; white arrows) before treatment (Fig. A, C, E, G, I), with a few microclots visible after treatment (Fig. B, D, F, H, J).

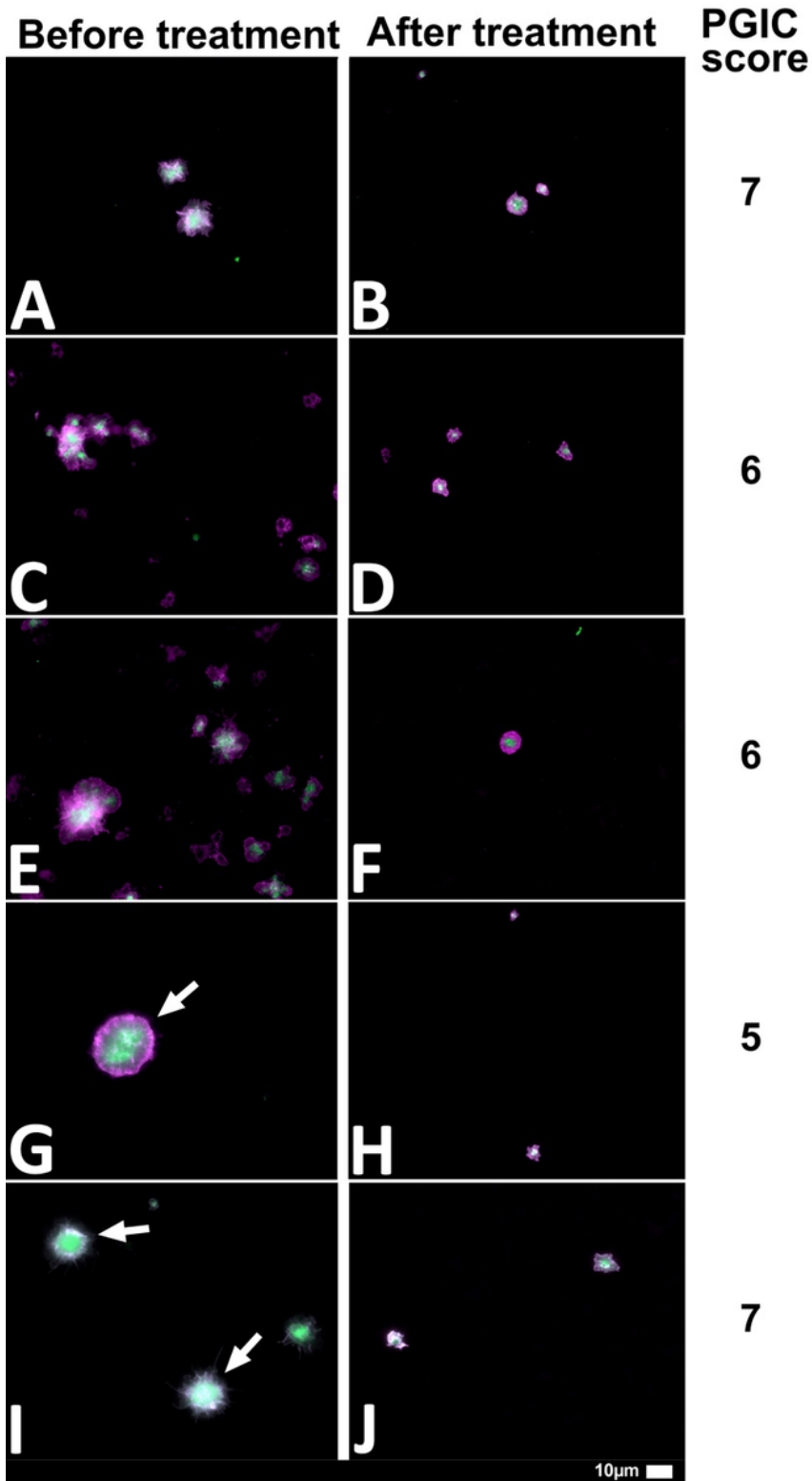


Figure 7

Representative fluorescence micrographs of platelet pathology before and after treatment. Moderate platelet spreading and mild platelet clumping (white arrows) were seen in treatment-naïve patients' samples (Fig. A, C, E, G, I) which improved after treatment, showing only mild platelet spreading and no clumps (Fig. B, D, F, H, J).

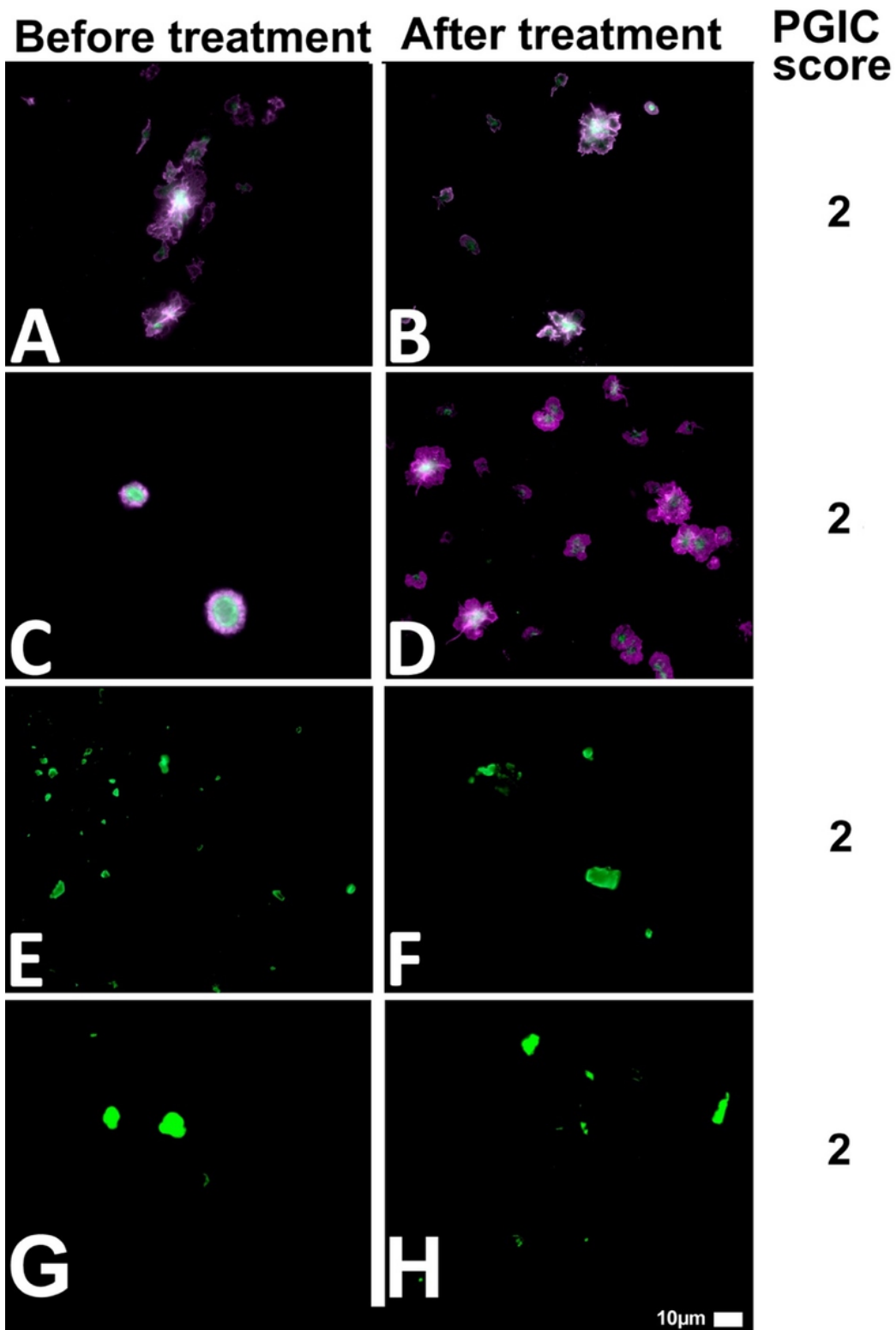


Figure 8

Representative fluorescence micrographs of platelet poor plasma (PPP) (E-H) and platelet pathology (A-D) before and after treatment in patients who reported no improvement in symptoms.

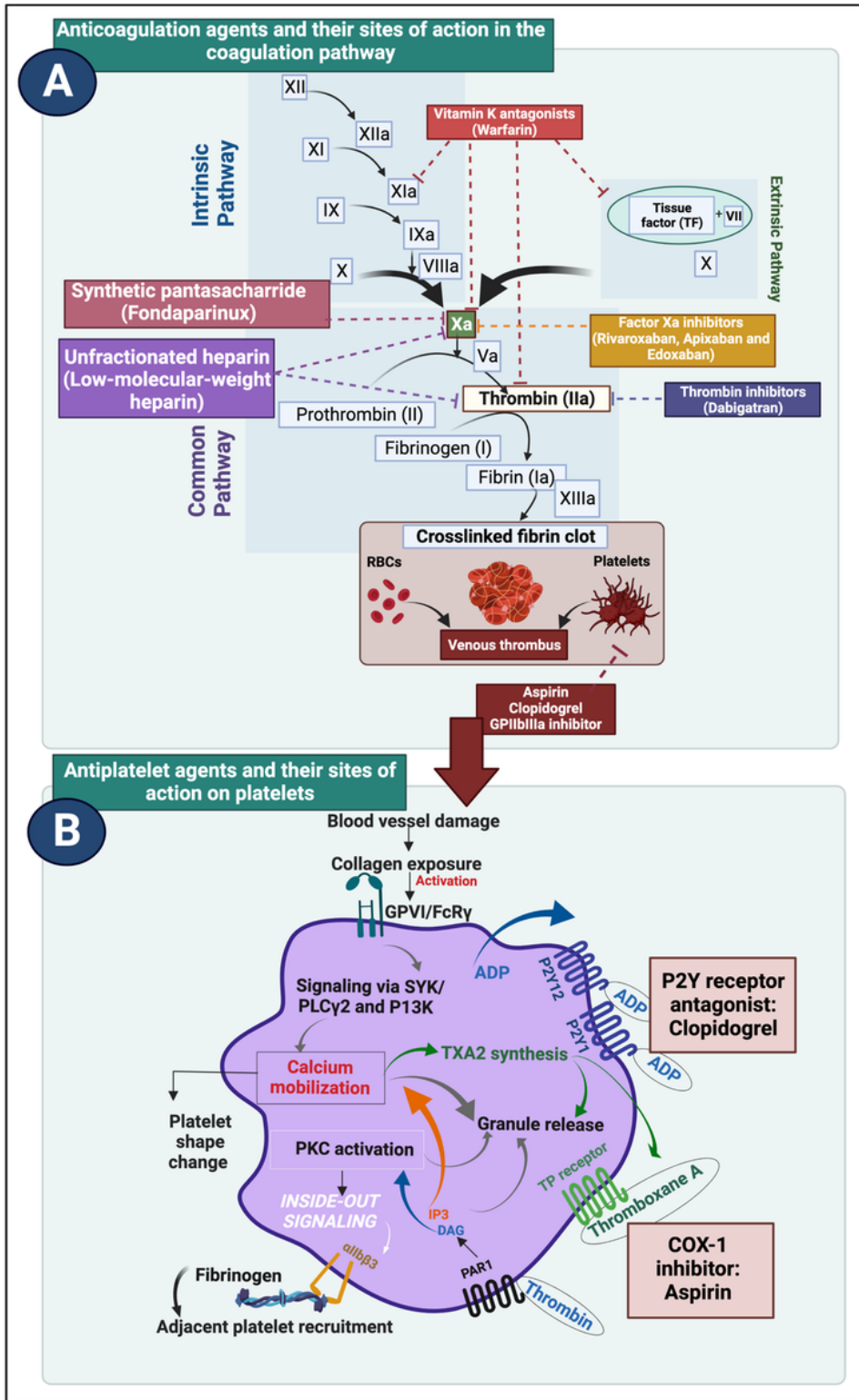


Figure 9

Effects of selected direct oral anticoagulants (DOAC) and dual antiplatelet therapy (DAPT) medication on clotting and platelet function. Diagram created with BioRender (<https://biorender.com/>).